



# Atlantoaxial Luxation

## Who can be affected?

All young small breed dogs with the Yorkie, Chihuahua, Toy Poodle and Japanese Chin being at higher risk. This disease can occur in large dogs as a result of a serious trauma like being hit by a car. In smaller breeds signs often start after jumping down from a small height or being dropped, but can also begin spontaneously.

## Cause

The atlas is the first vertebrae of the neck or cervical spine (C1) and is firmly attached to the skull. The axis is the second vertebrae of the cervical spine (C2). Unlike all the other vertebrae that are firmly connected to each other by an intervertebral disk, the atlas (C1) and axis (C2) are connected by just a piece of bone called the dens and multiple ligaments. The advantage of this unique connection (articulation) is that it allows for a much greater range of motion of the head compared to a traditional connection, however the connection can fail and the two vertebrae will then slip or slide into each other (luxation). This occurs when the dens or ligaments never form or are too small (aplasia, hypoplasia) or simply break. The resulting luxation causes damage to the lining to the spinal cord, spinal cord and brainstem.

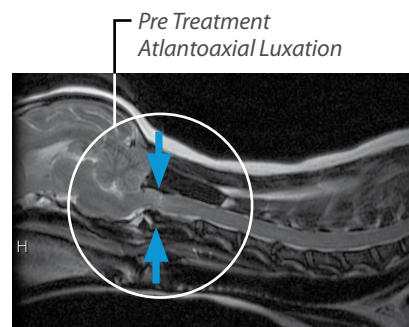
## Symptoms

Moderate to severe episodes of pain are the most common sign of an atlantoaxial (C1-C2) luxation. However, there can be a broad spectrum of persistent or episodic signs including weakness, head turn or tilt, and even seizure-like episodes. In fact, in small breed dogs presenting for seizure that have neck pain, this is a common diagnosis.

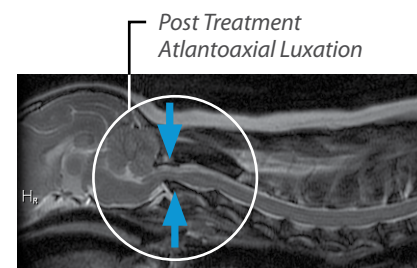
## Diagnostics

Radiographs made with the neck in different positions (neutral position, extended, slightly flexed) will demonstrate excess movement or luxation and indicate whether the dens has formed in a particular patient. MRI is also needed to assess spinal cord or brainstem damage and look for other common conditions that we see in small breed dogs such as Caudal Occipital Malformation Syndrome (COMS) and Meningoencephalitis (ME), additional information on these diseases is available at [www.bvns.net/disease](http://www.bvns.net/disease). A CT scan can be helpful to best assess the presence and location of the dens (which can be important if the fractured dens is going to be removed during surgery) and to assess for another potential problem at this location: displacement of C1 too far forward and compression of the brainstem. Lastly, a CSF analysis is occasionally performed to exclude inflammation or infection as the possible cause of the symptoms. Multiple tests are often recommended because often there is more than one diagnosis that must be considered prior to treatment.

**Initial presentation and one year follow-up MRI of a patient with atlantoaxial luxation. At presentation the patient showed some increase in signal in the spinal cord suggesting a luxation that then fell back into place. Treatment included use of a neck brace for six weeks, after which the neck pain and weakness improved. However, the neck brace only provided temporary relief as the patient again presented for neck pain one year later and the follow-up MRI shows a more severe pinching.**



Initial Presentation



One Year Follow-up

## Treatment

Six to eight weeks of crate rest while wearing a neck bandage that restricts movement of the C1-C2 joint can provide comfort and may allow torn ligaments to heal. The disadvantage of this treatment include: it only resolves the clinical signs about 50% of the time and is unlikely to work in dogs with severe signs (extreme weakness, severe pain), recurrence rates are about 40%, the bandage is cumbersome and by design must be restrictive to movement. Furthermore, severe skin infections can develop under the bandage especially if they get wet, and bandage changes are required every 1-2 weeks.

Surgery can also be performed where pins and bone cement are placed to prevent luxation. Surgery has about a 90% success rate, does not typically require a bandage and recurrence rates after surgery are low. Crate confinement for 6 weeks is still required. Unfortunately in the cases that fail the patients die from respiratory arrest and/or require a surgical revision.

Pain medication with an NSAID and pain modulators are prescribed with either management technique.

## Prognosis

The prognosis is typically good for control or resolution of clinical signs of disease. However, some patients require surgery to achieve a good outcome and some cases managed medically or surgically suffer respiratory arrest and death from this serious disease.



If you'd like further information on your pet's condition or to have our team involved in the care of your pet, please ask your veterinarian for a referral to BVNS. We have three convenient locations, onsite MRI at all locations and a team of neurologists available 24/7 and committed to providing you immediate care for your pet.

### Three Convenient Locations

**The LifeCentre**  
165 Fort Evans Road NE  
Leesburg, VA 20176  
P 703.669.2829  
F 703.669.2870

**Dogwood Veterinary Emergency  
& Specialty Center**  
5918 West Broad Street  
Richmond, VA 23230  
P 804.716.4716  
F 804.716.4814

**Regional Veterinary Referral Center**  
6651 Backlick Road  
Springfield, VA 22150  
P 703.451.3709  
F 703.563.9681

[www.bvns.net](http://www.bvns.net)